

Research Article

Diminution of Blue Color Vision in Type II Diabetes

Fatima Iqbal, OD, MPhil¹, Hashim Ali Khan, OD, FAAO^{2*}

¹The University of Faisalabad, Faisalabad, Pakistan

²Sehhat Foundation Hospital, Danyore, Gilgit, Pakistan

***Corresponding Author:** Hashim Ali Khan, OD, FAAO, Sehhat Foundation Hospital, Danyore, Gilgit, Pakistan,
E-mail: retinadr.hashimalikhan@gmail.com

Received: 10 February 2019; **Accepted:** 12 March 2019; **Published:** 14 March 2019

Abstract

Purpose: To determine blue color vision defect in type II diabetics and to compare it with the duration of diabetes.

Methodology: Cross-sectional study was conducted at Abdullah Memorial Hospital on 120 eyes of type-II diabetics in duration of 5 months from August 2018 to January 2019. Sample was collected through non-probability convenient sampling technique. Subjects with minimum 6/12 vision with or without correction were included and age group 35 to 65 years of both genders. Eye of diabetic type 2 without any sign of retinopathy were included. Any individual with congenital color vision defect, retinal, optic nerve or choroidal lesion was excluded. Ishihara plates were used initially to screen out congenital defects. Later, D-15 test was performed for evaluation of color vision for acquired changes due to diabetes. Data was entered using latest version 20 of SPSS and chi-square was used to assess association between color anomaly and type-II diabetes.

Results: In a sample of 120 eyes, 60% of population is Trichromate, 30% of population is tritanomalous, 1.7% population is deuteranomalous and 8.3% population is both deuteranomalous and tritanomalous. Comparison of blue color sensitivity in diabetic patients before onset of retinopathy was evaluated using Chi square with p value .000 at the level of 5% of confidence interval that shows highly significant results. Results conclude that there is strong association between blue color vision defects in diabetics. This defect was observed more with increase in duration of diabetes.

Conclusion: Study concluded that diabetic type 2 patients have impaired color vision specifically triatanomaly. Color vision must be evaluated and assessed in every diabetic patient and should be made an early assessment and screening tool. Timely assessment of color vision may detect tritanomaly earlier in type 3 diabetics.

Keywords: Color vision; Diabetes; Tritanomaly; Type II

1. Introduction

The human visual system samples the visible spectrum (about 400 to 700 nm) with a mosaic of three classes of photoreceptors, each sensitive to different wavelength ranges but largely overlapping. The receivers have peak sensitivities at short wavelengths (~440 nm), medium (~535 nm) or longer (~565 nm), and are called S, M and L cones, respectively. The different spectral sensitivities are determined by the specific photopigment molecule they contain [1]. A single receiver type cannot tell the difference between wavelength change and intensity change. The probability that a given photon is absorbed by a photopigment depends on the wavelength, but all subsequent events in the receiver are wavelength independent (the principle of clues). Thus, the wavelength information can only be extracted by comparing the responses between different receiver classes [2].

Macular degeneration is a disease that occurs in the elderly due to the normal aging process. It changes vision by destroying the retina. Diabetes can also damage the retina and cause tritanopia [3]. Diffuse color vision impairment in diabetics along both the blue/yellow and red/ green axis is affected. Such a defect is associated with additional inner retinal damage. Overall, color vision losses correlate with the degree of diabetic retinopathy or macular edema when these conditions are present. In many cases, however, they may precede clinically detectable retinal vascular abnormalities [4]. Insulin helps to break down and release sugar in the cells of your body. Sugar levels accumulate in your blood if you do not have enough insulin to break it down and known as hyperglycemia. Hyperglycemia can have a negative effect on every part of your body, including your eyes [5].

Cone dystrophy, types of maculopathy, lens changes associated with aging, diabetes, glaucoma, optic nerve diseases and traumatic brain injury can cause cardiovascular disease. For acquired CVDs, the type of defect may not be easy to classify; nevertheless, tritanopia predominates and the type and severity of the defect fluctuate during the course of the disease. Diabetic retinopathy (DR) is a primary cause of visual impairment worldwide [6]. Diabetes mellitus may be associated with ophthalmoscopically nonvisible neurovascular damage that progresses before the first clinical signs of DR appear. Reduction of the inner neuroretinal layer thickness on macular optical coherence tomography (OCT), reduced contrast sensitivity primarily at low spatial frequencies, abnormal results in color vision and microperimetry tests, and a prolonged implicit time recorded by multifocal electroretinography have been proposed for detection of early functional and nonvisible structural neuroretinal changes [7].

The general consensus of most previous studies is that diabetes mellitus leads to a lack of vision of tritan colors (i.e. a loss of discrimination along the blue/yellow axis). Tritan defects were explained by a higher susceptibility of short wavelength cones in the retina and early yellowing of the lens in the diabetic eye. Some studies, however, have reported an alteration of diffuse color vision in diabetic patients in which discrimination along the blue/yellow and red/green axes is affected. Such a defect would be associated with additional internal retinal lesions. Overall, color vision loss correlates with the degree of diabetic retinopathy or macular edema when these conditions are present

[8]. In many cases, however, they may precede clinically detectable retinal vascular abnormalities. To assess impairment of colour vision in type 2 diabetics with no diabetic retinopathy and elucidate associated risk factors in a population-based cross-sectional study. FM 100 hue-test was performed in 253 subjects with no clinical evidence of diabetic retinopathy. ICV found in diabetic subjects without retinopathy may be of non-vascular etiology [9]. Around three quarters of a century ago, Koenig, von Kries, Koellner and other German scientists using spectral devices had already studied the different forms of color vision impairment. However, these studies have been largely neglected, and only in recent years has there been renewed interest in this area, the first approach of which has been greatly facilitated by the D-15 Panel in the meantime the 100-Farnsworth Street. In general, almost all ocular diseases give rise to absorption systems, whereas lesions in the deep retinal layers cause a predominant reduction in the blue-yellow direction, and lesions in the ganglion layer and the optic nerve mainly cause red-green [10].

The Tritan anomaly is an acquired color defect known in diabetic patients, with or without clinical signs of diabetic retinopathy (DR). We report the case of a 45-year-old diabetic patient with a trit-aminated staining abnormality associated with obstructive sleep apnea and partial inversion with continuous positive airway pressure (CPAP) [10]. A 45-year-old man with diabetes, a wildlife photographer by profession, presented specific complaints of seeing all objects in the surroundings with a greenish hue in both eyes. He underwent a complete ophthalmological examination including the Farnsworth-Munsell 100 (FM 100) shade test, multifocal electroretinogram, micro-perimetry, optical coherence tomography (SDOCT) and arterial oxygen saturation. The subject had a low arterial oxygen saturation (PaO₂) of 86%. He was then informed of the inhalation of 100% oxygen for 15 min, after which he reported an improvement in his visual symptoms. FM 100, OCT and micro-perimetry were repeated after oxygenation [11]. He was referred to a specialized hospital for further evaluation of the cause of blood oxygen saturation and was advised for the sleep study, where he was diagnosed with obstructive sleep apnea (OSA) with an index of apnea-hypopnea of 20.9. The subject was informed of the weight loss measures and the oral application of continuous positive airway pressure. Since then, he has been under our regular supervision and has never known or complained of color vision problems [12]. This case report highlights the presence of systemic disorders such as obstructive sleep apnea in people with diabetes who may have color vision problems. Reduction of the inner neuroretinal layer thickness on macular optical coherence tomography (OCT), reduced contrast sensitivity primarily at low spatial frequencies, abnormal results in color vision and microperimetry tests, and a prolonged implicit time recorded by multifocal electroretinography have been proposed for detection of early functional and nonvisible structural neuroretinal changes. Vascular abnormalities such as changes in the retinal vessels caliber, architectural indices, and blood flow have been investigated to evaluate the early stages of DR [13]. The results of OCT angiography, retinal vessel oxygen saturation patterns, and elevated levels of circulating blood markers and cytokines have been suggested as early signs of diabetic retinopathy.

Type 2 diabetes mellitus accounts for 90% of diabetes cases and is associated with macro vascular and micro vascular complications of high morbidity and mortality. People at increased risk for type-II diabetes include those with impaired fasting glucose (IFG), glucose intolerance (IGT), and especially those with combined IFG and IGT. These people are part of a group known as pre-diabetic patients [14]. About 25% of people with prediabetes will

develop type 2 diabetes within three to five years. Hyperglycemia, in the absence of diabetes, is also associated with an increased risk of cardiovascular disease. Studies have shown that lifestyle changes and drug interventions are effective in delaying or preventing type 2 diabetes in pre-diabetic patients. Metformin is the drug of choice when medical treatment is warranted [15]. GI and IFG are associated with type 2 diabetes and despite the controversy; most studies reinforce the importance of these conditions in the development of micro- and macro-vascular diseases. Thus, therapeutic interventions in pre-diabetic patients are important in the primary prevention of type 2 diabetes and its chronic complications [16].

2. Methodology

Descriptive cross-sectional study was carried out on 120 eyes of type 2 diabetics in duration of 5 months from August 2018 to January 2019 at Abdullah Memorial Hospital, Faisalabad. Non-probability Convenient sampling technique was used to scrutinize whole population and subjects with minimum 6/12 vision with or without correction was included and age group 35 to 65 years of both genders. Eye of diabetic type 2 without any sign of retinopathy were included. Any individual with congenital color vision defect, retinal, optic nerve or choroidal lesion was excluded. Subjects reported in outpatient department and willing to participate were included in this study. Consent was obtained and ethical review was done according to the Declaration of Helsinki. Slit lamp examination was performed for anterior and posterior segment examination to exclude corneal opacity, lenticular opacity or any other ocular pathology. Fundus was examined for the exclusion of diabetic retinopathy. Ishihara plates were used initially to screen out congenital defects. Later, D-15 test was performed for evaluation of color vision for acquired changes due to diabetes. Test was performed thrice and an average result was considered. Data was entered using latest version 20 of SPSS and chi-square was used to assess association between color anomaly and type 2 diabetes.

3. Results

120 eyes of age 35-65 years old subjects were included in study. Age distributed in 3 groups out of which 30% (36) belongs to age group of 35-45 years of age. There are 36.7% (44) eyes from 46-55 years of age. And 33.3% (40) eyes from 56-65 years of age. Male and females both gender were included in study and 53.3% male and 46.7% females. Figure 1 showed percentage of presence of diabetes among total population. 55% of population is diabetic and 45% is non-diabetic.

	Age group	Frequency	Percent	Valid Percent	Cumulative Percent
Valid	35-45years	36	30.0	30.0	30.0
	46-55years	44	36.7	36.7	66.7
	56-65years	40	33.3	33.3	100.0
	Total	120	100.0	100.0	-

Table 1: Age Distribution.

Gender		Frequency	Percent	Valid Percent	Cumulative Percent
Valid	Male	64	53.3	53.3	53.3
	Female	56	46.7	46.7	100.0
	Total	120	100.0	100.0	-

Table 2: Gender Distribution.

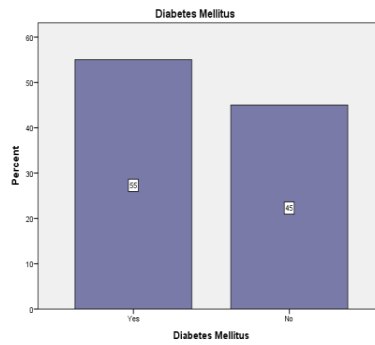


Figure 1: Presence of Diabetes.

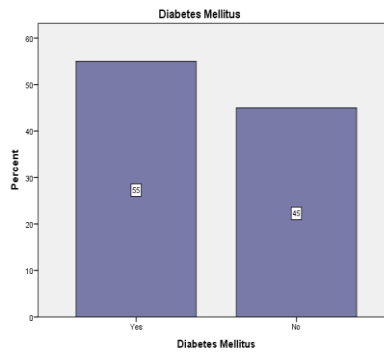


Figure 2: Duration of Diabetes.

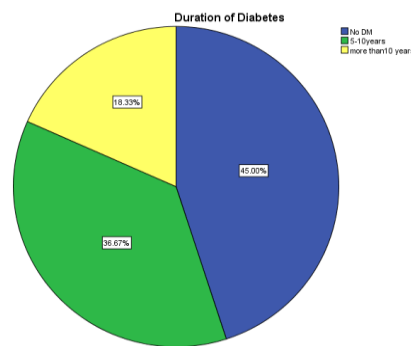


Figure 3: Total 55% population is diabetic and 36.7% population is diabetic from 5-10 years of age and 18.3% population is diabetic from more than 10 years of age.

Figure 4 showed 60% of population is Trichromate. 30% of population is tritanomalous, 1.7% population is deuteranomalous and 8.3% population is both deuteranomalous and tritanomalous.

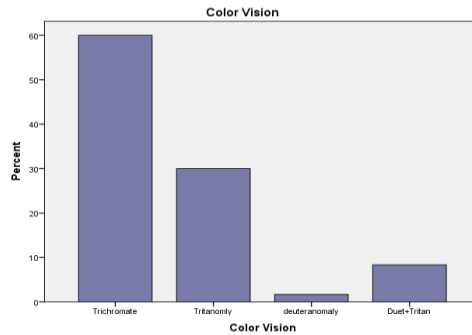


Figure 4: Frequency of color vision defects.

Cross tabulation of color vision and diabetes as shown below.

Color Vision	Diabetes Mellitus		Total
	Yes	No	
Trichromate	22	50	72
Tritanomaly	32	4	36
Deuteranomaly	2	0	2
Duet+Tritan	10	0	10
Total	66	54	120

Table 3: Crosstabulation between color vision and diabetes.

Comparison of blue color sensitivity in diabetic patients before onset of retinopathy is evaluated using Chi square with p value 0.000 at the level of 5% of confidence interval that shows highly significant results. Results conclude that there is strong association between blue color vision defects in diabetics.

4. Discussion

Results of this study showed higher association of blue color defect in type 2 diabetics. Laxmi Gella et al conducted a population based cross sectional study between 2007-2010 to assess the impairment of color vision in type 2 diabetics without retinopathy and demonstrated associated risk factors. Population of 253 subjects was included in study. Detailed ophthalmic examination was performed including cataract grading. P value of <0.05 demonstrated significant results. Risk factors for impaired color vision were OR 1.79 in women. They concluded that impaired color vision is early indicator of neurodegenerative changes in retina before clinically visible retinopathy [17]. Another cross sectional study was conducted by M Radwan in 2015 to assess acquired color vision defects in diabetics at different stages of retinopathy with age matched healthy individuals. Ishihara pseudoisochromatic test as quantitative and D15 panel test as qualitative test were performed by all study population. Only 10% control eyes

failed D15 test while 34% diabetic eyes failed the test [13]. Results showed tritan defect was the most encountered defect among all. Another study conducted in 2010 by Heravian et al. to detect functional losses in diabetics without retinopathy [18].

Contrast sensitivity and D15 panel test was performed by all included individuals to assess visual functions. Total number of subjects was 105 out of which 70 were diabetic among them 35 had retinopathy and 35 were without retinopathy and rest was control group. Findings suggest that appropriate choice of test can be very helpful in screening method for diabetics for early detection of retinopathy before clinical appearance. In 2013 Sun and Zhang conducted a study for the same purpose of assessment of color vision in diabetics with sample size of 78 individuals (126 eyes) and 64 healthy individuals were selected as healthy controls [19]. Fransworth Munsell 100 hue test was used and with spearsman rank correlation it is analyzed that color defects appear at early stages in diabetes and color discrimination plays important role in color perception and visual function damage in diabetics [20]. Current study also adopted cross sectional design with convenient sampling method subjects reported in study location. Sample size of this study is 120 subjects out of which 66 are diabetics and 54 control age matched groups, sample size of this study matches previous studies conducted in past years and followed nearly same procedures.

Zghal-Mokni et al. [17] conducted a multicentric prospective study in 2008 of representative population of 285 subjects they performed complete ophthalmological examination and laboratory tests on study population and analyzed their data with Chi square method and Fischer man technique and concluded that regular ophthalmological examination is necessary to prevent ocular complications of diabetes. In current study statistical analysis is carried out by Chi square method usin cross tabulations on spss version 21, significant results are obtained by this analysis that gives the strong association of color vision defect in diabetics without retinopathy with p-value of 0.000 [21]. Shoji T conducted a study in 2008 to understand the reference values and discrimination values of color vision function. Male army officials were selected and underwent Ishihara pseudoisochromatic test, D15 panel and standard pseudoisochromatic plates part 2. The Frans worth munsell 100 hue test and criteria of verriest et al were used as definitive. Color confusion index was used to calculate outcomes of D15. Statistical analysis proved that color confusion index is in good agreement with acquired color vision impairment and D15 test is helpful in screening purposes. Diabetic patients usually develop visual function defects specially color vision for this purpose Tan et al. conducted a study on multi ethnic Asian population, diagnosed cases of diabetes from minimum of 2 years. D15 color test was used to assess color vision of study population. Data analyzed with logistic regression concluded that mostly tritan defect is noted and it is associated with age and education level of subject. Early screening can prevent permanent visual disturbance. Feitosa-Santana et al. in 2010 conducted a study and used D15 panel test as screening tool in assessment of color vision in diabetics and concluded prior assessment of retinopathy is possible with color perception and discrimination ability [20]. D15 test as proved to be the good screening test for the evaluation of color vision in diabetics. Current study proved this association with significant results analyzed statistically.

Cone dystrophy, maculopathy, age related lenticular changes, diabetes mellitus, glaucoma, optic neuritis and traumatic head and brain injuries can cause impaired color vision. For acquired color vision defect, it is not easy to classify type or color vision defect. Predominantly it is tritanopia and type and severity of the defect fluctuates during the disease. Diabetes mellitus leads to blue/ yellow axis defects (tritanomaly) that patient loses discrimination along the blue/yellow axis. Tritan color defects are explained by higher vulnerability of blue short-wavelength cones in the retina. Such defect would be associated with additional internal retinal lesions. Overall, color vision loss is associated with the severity of diabetic retinopathy and macular edema. In many cases they may forego clinically detectable vascular diseases of retina. Raman, Srinivasan and Nagarajan conducted case study in 2016 on diabetic subject with obstructive sleep apnea and evaluated color vision with Farnsworth Munsell 100 Hue Test and concluded that diabetic patients with obstructive sleep apnea present with color vision problems. This current study correlates its results with previous studies. Current study showed that 50% of diabetics were affected with blue color vision defect. Five percent of control groups were assessed with tritan defect. It tells us about tritan color defects in diabetics before clinically visible retinopathy for the prevention of irreversible damages to retina and thereby supports treatment strategy. This helps patients in making profession choices easy whom color vision is affected and helps them to overcome emotional trauma.

5. Conclusion

Results of this study concluded that diabetic type 2 patients have impaired color vision specifically tritanomaly. Color vision evaluation with good screening color vision test i.e. D15 panel test impairment can be detected even before clinically visible diabetic retinopathy. Early detection allows prevention of vascular changes in retina. All the diabetic patients should be given proper awareness and health education regarding color vision deficiency. Color vision must be evaluated and assessed in every diabetic patient and should be made an early assessment and screening tool. Color vision plays an important role in subjects with diabetes to reliably self-monitor the blood and urine glucose levels. Timely assessment of color vision may detect tritanomaly earlier in type 2 diabetics.

References

1. Raman R, Srinivasan S, Nagarajan R. Structural and functional retinal abnormalities in type 2 diabetes with obstructive sleep apnea. *Sleep and Breathing* 20 (2016): 1005-1007.
2. Souza C, Gross J, Gerchman F, et al. Pre-diabetes: Diagnostico, avaliacao de complicacoes cronicas e tratamento. *Arquivos Brasileiros de Endocrinologia and Metabologia* 56 (2012): 275-284.
3. Francois J, Verriest G. On acquired deficiency of colour vision, with special reference to its detection and classification by means of the tests of Farnsworth. *Vision Research* 1 (1961): 201-219.
4. Gella L, Raman R, Kulothungan V, et al. Impairment of Colour Vision in Diabetes with No Retinopathy: Sankara Nethralaya Diabetic Retinopathy Epidemiology and Molecular Genetics Study (SNDREAMS- II, Report 3). *PLOS ONE* 10 (2015): 0129391.
5. Mahjoob M, Ostadimoghaddam H, Heydarian S. Color vision deficiency. *Journal of Gorgan University of Medical Sciences* 18 (2018): 1-7.

6. Alrasheed S, EL Awad M, Abdulbagi A, et al. Congenital and acquired colour vision deficiency among population in North Kordofan State of Sudan. *Sudanese Journal of Ophthalmology* 9 (2017): 22.
7. Gualtieri M, Feitosa-Santana C, Lago M, et al. Early visual changes in diabetic patients with no retinopathy measured by color discrimination and electroretinography. *Psychology & Neuroscience* 6 (2013): 227-234.
8. Safi H, Safi S, Hafezi-Moghadam A, et al. Early Detection of Diabetic Retinopathy. *Survey of Ophthalmology* 63 (2018): 601-608.
9. Jonczyk-Skorcka K and Kowalski J. The evaluation of color vision and its diagnostic value in predicting the risk of diabetic retinopathy in patients with glucose metabolism disorders. *Polish Merkuriusz Lekarski: Organ of the Polish Medical Society* 43 (2017): 15-21.
10. O'Neill-Biba M, Sivaprasad S, Rodriguez-Carmona M, et al. Loss of chromatic sensitivity in AMD and diabetes: a comparative study. *Ophthalmic and Physiological Optics* 30 (2010): 705-716.
11. Gregori B, Papazachariadis O, Farruggia A, et al. A differential color flicker test for detecting acquired color vision impairment in multiple sclerosis and diabetic retinopathy. *Journal of the Neurological Sciences* 300 (2011): 130-134.
12. NORTH R. Does hyperglycaemia have an influence upon colour vision of patients with diabetes mellitus?. *Ophthalmic and Physiological Optics* 17 (1997): 95-101.
13. Radwan TM, Ghoneim EM, Ghobashy AW, et al. Assessment of Color Vision in Diabetic Patients. *International Journal of Ophthalmic Research* 1 (2015): 19-23.
14. Heravian J, Shoeibi N, Azimi A, et al. Evaluation of Contrast Sensitivity, Color Vision and Visual Acuity in Patients with and without Diabetes. *Iranian Journal of Ophthalmology* 22 (2010): 33-40.
15. Kurtenbach A, Wagner U, Neu A, et al. Brightness matching and colour discrimination in young diabetics without retinopathy. *Vision Research* 34 (1994): 115-122.
16. Tan N, Yip W, Kallakuri S, et al. Factors associated with impaired color vision without retinopathy amongst people with type 2 diabetes mellitus: a cross-sectional study. *BMC Endocrine Disorders* 17 (2017).
17. Zghal-Mokni I, Nacef L, Letaief I, et al. Ocular manifestations of diabetes: 285 cases. *La Tunisie Medicale* 86 (2008): 1004-1007.
18. Shoji T, Sakurai Y, Sato H, et al. Do type 2 diabetes patients without diabetic retinopathy or subjects with impaired fasting glucose have impaired colour vision? The Okubo Color Study Report. *Diabetic Medicine* 28 (2011): 865-871.
19. Andrade L, Souza G, Lacerda E, et al. Influence of retinopathy on the achromatic and chromatic vision of patients with type 2 diabetes. *BMC Ophthalmology* 14 (2014).
20. Feitosa-santana C, Oiwa N, Paramei G, et al. Color space distortions in patients with type 2 diabetes mellitus. *Visual Neuroscience* 23 (2006): 663-668.
21. Sun T and Zhang M. Characteristics of color discrimination changes in diabetic patients without diabetic retinopathy. *Chinese Journal of Ophthalmology* 49 (2013): 41-46.

Citation: Fatima Iqbal, Hashim Ali Khan. Diminution of Blue Color Vision in Type II Diabetes. Journal of Ophthalmology and Research 2 (2019): 010-019.



This article is an open access article distributed under the terms and conditions of the [Creative Commons Attribution \(CC-BY\) license 4.0](https://creativecommons.org/licenses/by/4.0/)